

Successful Treatment of Giant Nevus Spilus using a Q-Switched Nd: YAG Picosecond Domain Laser

Fabián Pérez Rivera

Plastic surgeon, Buenos Aires, Argentina

Abstract: Background: Nevus spilus (NS) is a congenital or early-childhood condition that is relatively uncommon. It is characterized by a pigmented lesion consisting of dark, hyperpigmented dots scattered over a tan-colored macule. This lesion is usually located on the trunk, extremities, or along the lines of Blaschko. NS are typically small in size, but may occasionally form a large unilateral plaque or generalized form that involves a considerable portion of the body. Large or giant NS can seriously affect a person's appearance and self-esteem, especially if located on exposed parts of the body. Different therapies for NS have been described, including conventional surgery, chemical peels, mechanical dermabrasion, and ablative and non-ablative lasers. **Methods:** Due to aesthetic and psychological concerns, a 27-year-old female born with a giant NS completely covering the right lower extremity was treated with a non-ablative Q-switched Nd:YAG picosecond domain laser in order to reduce the color of the nevus. **Results:** After five sessions of laser treatment, a complete reduction of the café au let and dark spots treated area was obtained. No recurrence was observed after a 1-year follow-up. **Conclusion:** The Q-switched Nd:YAG picosecond domain laser appears to be a safe and effective treatment for giant NS.

Keywords: Nevus spilus, Giant Spilus Nevus, Q-switched Laser Treatment and Q-switched Picoseconds Domain Laser Treatment.

INTRODUCTION

Nevus spilus (NS) is a congenital or early-childhood condition that is relatively uncommon. It is characterized by a pigmented lesion consisting of dark, hyperpigmented dots scattered over a tan-colored macule. This lesion is usually located on the trunk, extremities, or along the lines of Blaschko (1).

Blaschko's lines are paths of normal cell development in the skin. These lines are invisible under normal conditions. They become apparent when some diseases of the skin or mucosa manifest according to these patterns. They follow a "V" shape over the back, "S" shaped whirls over the chest and sides, and wavy shapes on the head. These lines are believed to trace the migration of embryonic cells (2).

NS is also referred as "speckled lentiginous nevus," "zostiform lentiginous nevus," or "spotty nevus" (3). The total incidence in newborns is 0.2% and 1-2% during early childhood. Both sexes are affected equally. It can present as a junctional nevus, compound nevus, Spitz nevus, or blue nevus (4).

Usually, NS are small in size. Café au let spots average 1-4 cm in diameter, while pigmented spots average 1-6 mm in diameter. Occasionally, NS can consist of a large unilateral plaque or generalized form that involves a considerable portion of the body (4). The giant NS form, size bigger than 20 cm², may represent a substantial cosmetic morbidity and pose treatment challenges.

Different treatments have been described for NS, including conventional surgery, chemical peels, mechanical dermabrasion, and ablative and non-ablative lasers (5). Some of these options may lead to complications, such as anesthetic scars, hypertrophic scars, keloids, and transitory or permanent hypopigmentation or hyperpigmentation (6). Of these therapies, successful treatment using different kinds of ablative and non-ablative laser alone or combination have been

reported (5,7,8,9,10,11). It can be observed a comparative table about pros and cons of each different treatment on table 1.

	Pros	Cons
Cryosurgery	Fast	Pain; Scars; Permanent hypopigmentation; Topical anesthesia
Conventional surgery	Fast; Non-hypo/hyperpigmentation	Pain; Scars; Local or General anesthesia; Surgery room
Chemical peels	Cheap; Non-scars	Hypo/hyperpigmentation; Slow (need several sessions)
Mechanical dermabrasion	Fast	Pain; Scars; Local or General anesthesia; Surgery room
Ablative laser	Few sessions	Scars; Hypo/hyperpigmentation; Topical anesthesia
Q-Switched laser	Non-scars	Transitory PIH; Slow (several sessions)

Table 1: Spilus Nevus Treatments.

Even though there are numerous reports of different kinds of treatments, there remains some controversy regarding the malignant potential of NS (12,13). The aim of this publication is describe a successful non-ablative Q-switched laser (QSL) Nd:YAG picosecond domain treatment on a giant NS completely covering a lower extremity with no recurrence after a 1 year of follow-up.

METHODS

A 27-year-old female with clinical diagnosis of giant NS completely covering her right lower extremity who had not undergone previous treatment requested a therapy to improve the color of her lesion due to aesthetic and psychological concerns. After informed consent was obtained, started testing part of the macula to obtain a therapeutic laser result.

*Address correspondence to this author at the Plastic surgeon, Buenos Aires, Argentina; Email: fabian@perezrivera.com.ar

From February 2019 to June 2019, the patient underwent a total of five monthly treatment sessions with the QSL Nd:YAG picosecond domain (picoPlus, Lutronic Company). Photographs of the affected area were obtained before treatment and at 1 year of follow up since the last treatment session. In agreement with the patient, a control area on the upper thigh remained untreated for comparison.

The parameters chosen in all sessions were 1064 nm wavelength, 10 Hz, 7 mm beam at an intensity of 2.0 joules. Cold air refrigeration at 4°C (Cryo 6, Zimmer) was utilized during the treatment. After each session, the patient was told to moisten the treated area with vaseline and avoid sun exposure. No antibiotics or other indications were suggested.

RESULTS

After five sessions of laser treatment, a complete reduction of the café au lait and dark spots of the treated area was obtained (Figure 1).

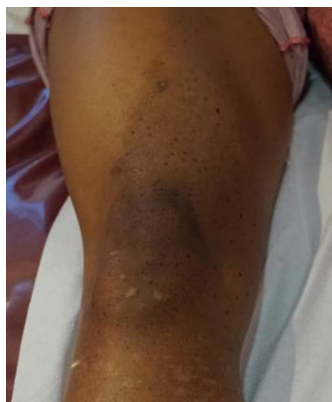

Figure 1(a): 27 years old female with giant spilus nevus on right lower extremity. Right thigh pretreatment photography. The white spots near knees were previous test with the Q-switched Nd:YAG picosecond domain lasers before start treatment.

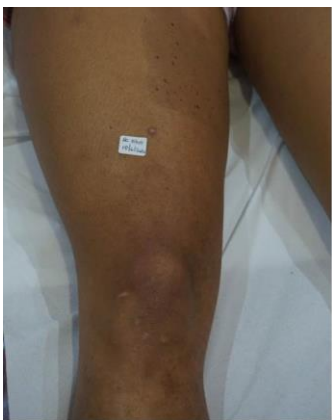

Figure 1(b): After 5 sessions Q-switched Nd:YAG picosecond domain lasers it obtained a complete reduction of the pigmented lesion. In agreement with the patient the upper part of the spilus nevus was keeping without treatment as a control area.

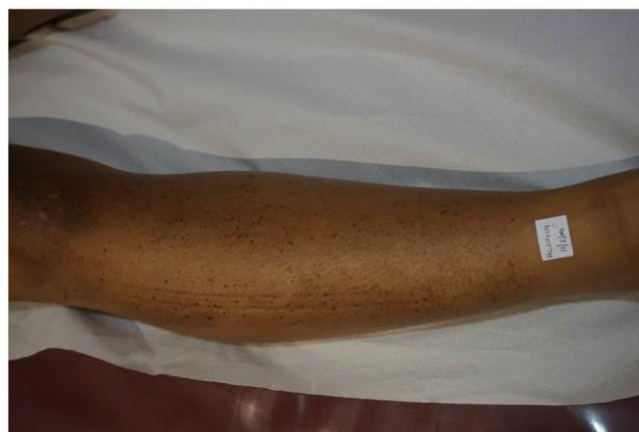

Figure 1(c): Right leg pretreatment photography. The white spots near knees were previous test with the Q-switched Nd:YAG picosecond domain lasers before start treatment.

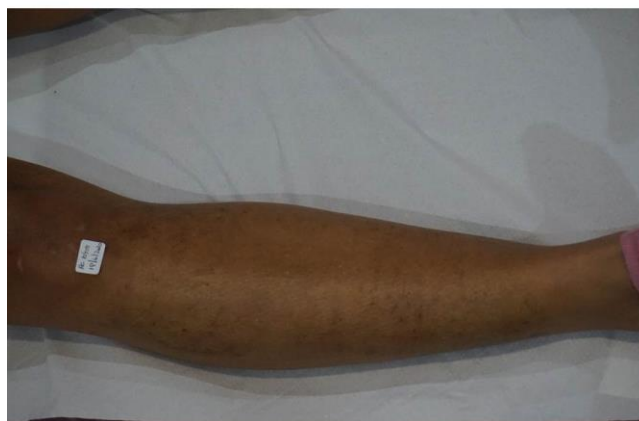

Figure 1(d): After 5 sessions Q-switched Nd:YAG picosecond domain lasers it obtained a complete reduction of the pigmented lesion.

Pain during treatment was well-tolerated with the cold air supply only. No side effects or complications were noted. After 1 year of follow up since the last treatment session in June 2019, no relapse of the NS was observed. The patient rated the results as excellent, exceeding expectations she had before starting the treatment.

DISCUSSION

Pigmented nevi, both congenital and acquired, are the most common benign tumors of the skin. They may occur on any part of the skin. In comparison, the incidence of NS is low. Giant NS, can seriously affect a person's appearance and self-esteem, especially when located on exposed parts of the body. For this reason, our patient sought a cosmetic solution.

Various publications have reported different types of procedures that improve large or giant NS. Lasers result in fewer complications and better results compared to other treatments modalities (e.g., surgical excision, dermabrasion, chemical peels). Some of the lasers that have been used to treat NS include intense pulsed light (9), a vascular laser pulsed dye laser (8), fractional CO₂ laser (4), and QSL (12).

After critical evaluation of the literature, the most preferred laser technology for treating larger NS is QSL (5,7,10,12). QSL provides skin improves without scarring or texturing changes of the skin for a range of benign hyperpigmented disorders. QSL has a specific chromophore target: melanin and any other pigmented particles, such as tattoo ink. Among the Q-switched lasers, there are substantial differences relating to the pulsed width, including the nanosecond domain (ns domain) and picosecond domain (ps domain). The ns domain laser has a considerable photocoagulation effect and even a photoacoustic effect. The ps domain laser provides a nearly complete photoacoustic effect, which is why the ps domain laser does not transfer heat to the surrounding tissue (figure 2). Thus, it is rare to observe

permanent hypopigmentation or hyperpigmentation after treatment with the ps domain laser, which is not the case for ns domain lasers (14,15,16).

No reference was found describing a giant NS treated with QSL Nd:YAG ps domain laser. Although Greveliket at. (1997) described focal recurrence in one NS patient treated by QSL, this was not the case for our patient, who is still free of the lesion after 1 year of follow-up after the last laser session (7).

Although there is some controversy regarding the malignant potential of NS, no deleterious effects, such as malignant transformation of melanocytic or nevomelanocytic lesions by QSL, have been reported (7).

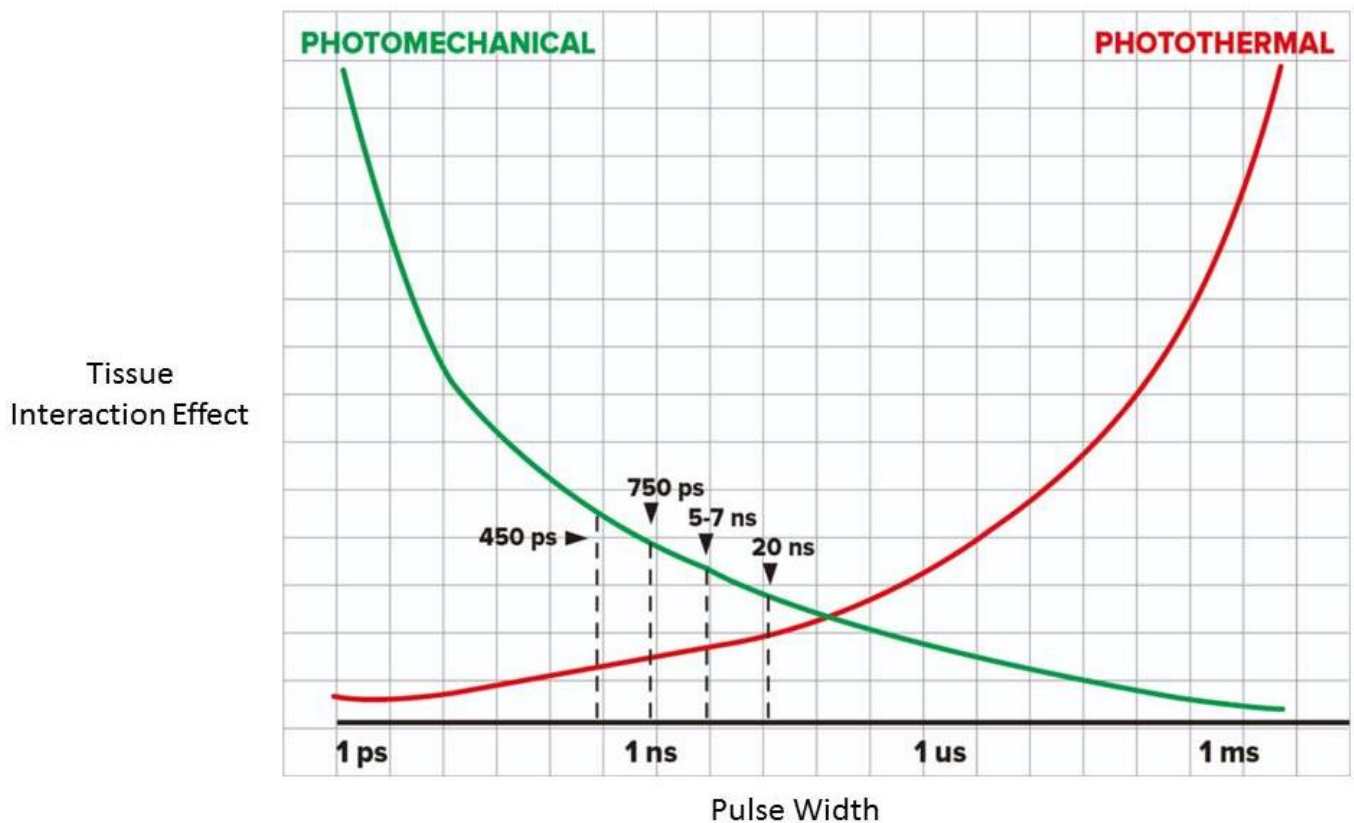


Figure 2: Difference between Q-switched lasers domains. Closer the pulse width is to the picosecond domain, more photoacoustic effect and less or non-photocoagulation effect. Opposite, closer the pulsed width is to the nanosecond domain, more photocoagulation effect even so photoacoustic effect.

CONCLUSIONS

Giant NS is an uncommon benign pigmented lesion that seriously affects a person's appearance and self-esteem. NS deserves a medical solution. Among all the treatments for NS in the literature, QSL has been demonstrated to be the more effective procedure. No references of a giant NS treated by QSL Nd:YAG ps domain were found in the literature.

In this case report a total removal of the pigmentation after treatment by QSL Nd:YAG ps domain was obtained in a giant NS completely covering the right lower extremity with no recurrence after 1 year of follow-up. Although the appearing of melanoma NS is uncommon, the author instructed the patient to undergo continued periodic cancer screening.

ETHICAL STATEMENTS

Conflict of Interest: The author declares that he has no conflict of interest. **Ethical approval:** All procedures performed in studies involving human participants were in accordance with the ethical standards of the institutional and/or national research committee and with the 1964 Helsinki Declaration and its later amendments or comparable ethical standards. For this kind of retrospective observational study no ethical approval is required. **Informed consent:** Informed consent was obtained from the patient included in the study. **Patient consent:** Patient signed informed consent regarding publishing their data and photographs. **Funding:** none. **Level of Evidence:** Level IV, therapeutic study.

REFERENCES

- [1] Cohen HJ et al. Nevus spilus Arch Derm 1970; 120:433-437.
<https://doi.org/10.1001/archderm.102.4.433>
- [2] Suárez-Peñaranda JM et al. Unusual Interface Dermatoses Distributed Along Blaschko's Lines in Adult Patients. Am J Dermatopathol. 2017 Feb; 39(2):144-149.
<https://doi.org/10.1097/dad.0000000000000689>
- [3] Vaidya DC et al. Nevus spilus. Cutis 2007; 80(6):465-468.
https://doi.org/10.1007/springerreference_110319
- [4] Tang M et al. Venus spilus: treatment with fractional CO2 laser in combination with MedLite C6 laser: a preliminary study. Laser Med Sci. Dec 2016.
<https://doi.org/10.1007/s10103-016-2128-z>
- [5] Moreno-Arias GA et al. Treatment of widespread segmental nevus spilus by Q-switched alexandrite laser (755nm, 100 nsec). DermatolSurgsept 2001; 27:841-843.
<https://doi.org/10.1097/00042728-200109000-00012>
- [6] Orentreich N, Orentreich DS. Dermabrasion as a complement to dermatolo. ClinPlastSurg 1998; 25:63-80.
[https://doi.org/10.1016/s0094-1298\(20\)32521-9](https://doi.org/10.1016/s0094-1298(20)32521-9)
- [7] Grevelink JM et al. Treatment of nevus spilus with the Q-switched ruby laser. Dermatol Surg 1997; 23:365-370.
<https://doi.org/10.1111/j.1524-4725.1997.tb00062.x>
- [8] Abrusci V, Benzecry V. Medium-sized nevus spilus of the neck treated with pulsed dye laser. Dermatologic Therapy. 2017; 00:e 12497.
<https://doi.org/10.1111/dth.12497>
- [9] Gold MH, Foster TD, Bell MW. Nevus spilus successfully treated with an intense pulsed light source. DermatolSurg 1999; 25: 254-5.
<https://doi.org/10.1046/j.1524-4725.1999.08192.x>
- [10] Waldorf H, Kauvar A, Geronemus G. Treatment of small and medium congenital nevi with the Q-switched ruby laser. Arch Dermatol 1996; 132:301-4.
<https://doi.org/10.1001/archderm.1996.03890270077011>
- [11] Alster TS Complete elimination of large café-au-lait birthmarks by the 510-nm pulsed dye laser. Plastic Reconstructive Surgery. 1995;96:1660-1664.
<https://doi.org/10.1097/00006534-199512000-00020>
- [12] Kar H, Gupta L. Treatment of nevus spilus with Q switched Nd:YAG laser. Indian J Dermatol Venereol Leprol 2013; 79:243-5.
<https://doi.org/10.4103/0378-6323.107650>
- [13] Abecassi S et al. Melanoma within naevus spilus: 5 cases. Ann. Dermatol. Venereol. 2006; 133:323-328.
- [14] Perez Rivera, F. Tratamiento lesiones pigmentarias melanocíticas y no melanocíticas con láser de picosegundos. Chapterbook. Arreola I, Huerta Rivera, G "Láser y Luces en Dermatología". Ed. Permanyer. In press.
- [15] Lee HJ et al. Postinflammatory hyperpigmentation successfully treated with 1064-nm picosecond-domain Neodymium:Yttrium-Aluminum-Garnet laser. Med Laser 2018; 7(1): 52-54.
- [16] Goo BL, Cho SB. Efficacy and safety of picosecond-domain neodymium-doped yttrium aluminum garnet laser treatment on various causes of traumatic tattoos. Med Laser 2016; 5(2):90-95.
<https://doi.org/10.25289/ml.2016.5.2.90>

Received on 04-08-2020

Accepted on 30-08-2020

Published on 01-10-2020

DOI: <https://doi.org/10.31907/2414-2093.2020.06.01>

© 2020 Fabián Pérez Rivera; Licensee Green Publishers.

This is an open access article licensed under the terms of the Creative Commons Attribution Non-Commercial License (<http://creativecommons.org/licenses/by-nc/3.0/>) which permits unrestricted, non-commercial use, distribution and reproduction in any medium, provided the work is properly cited.